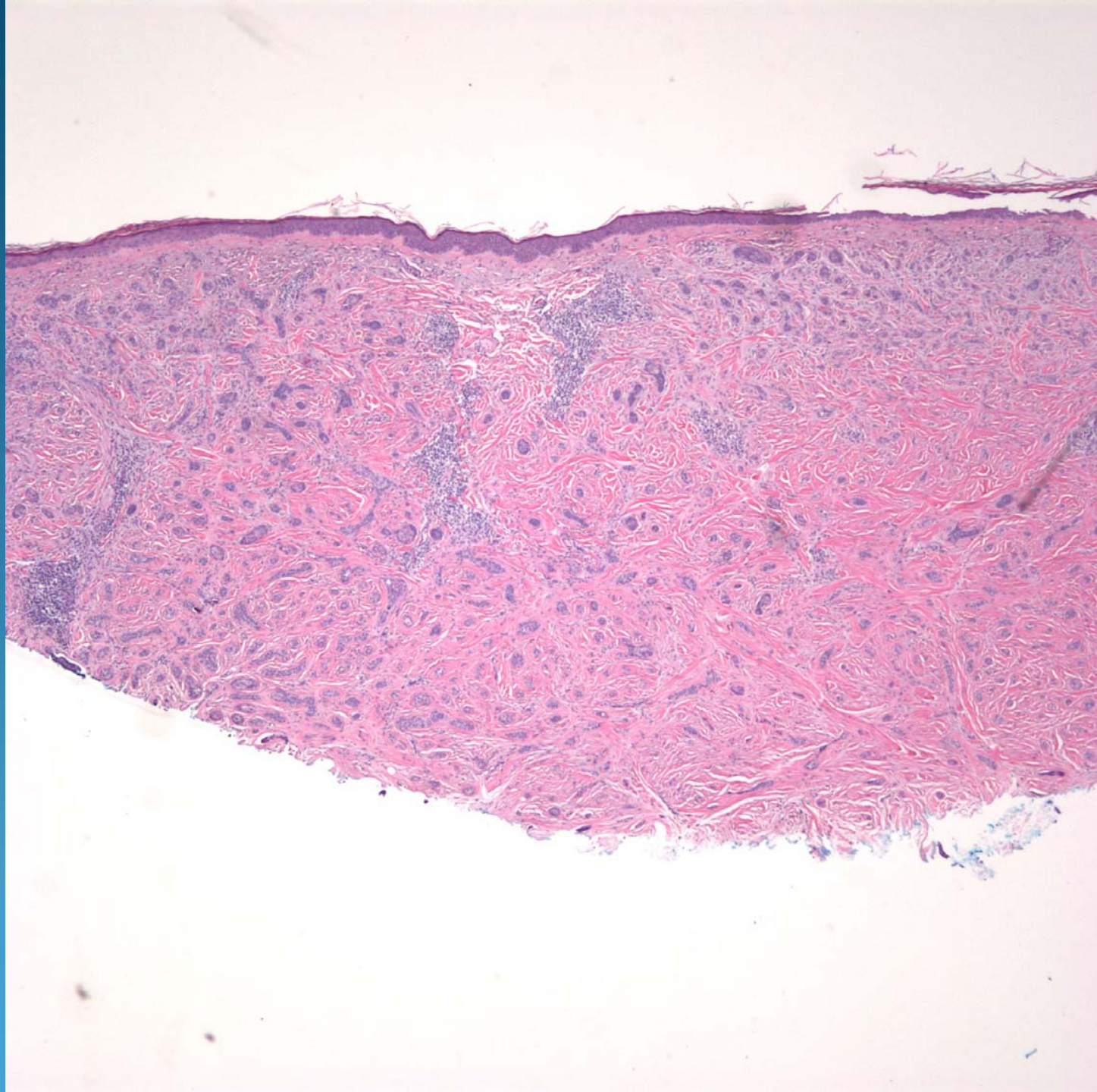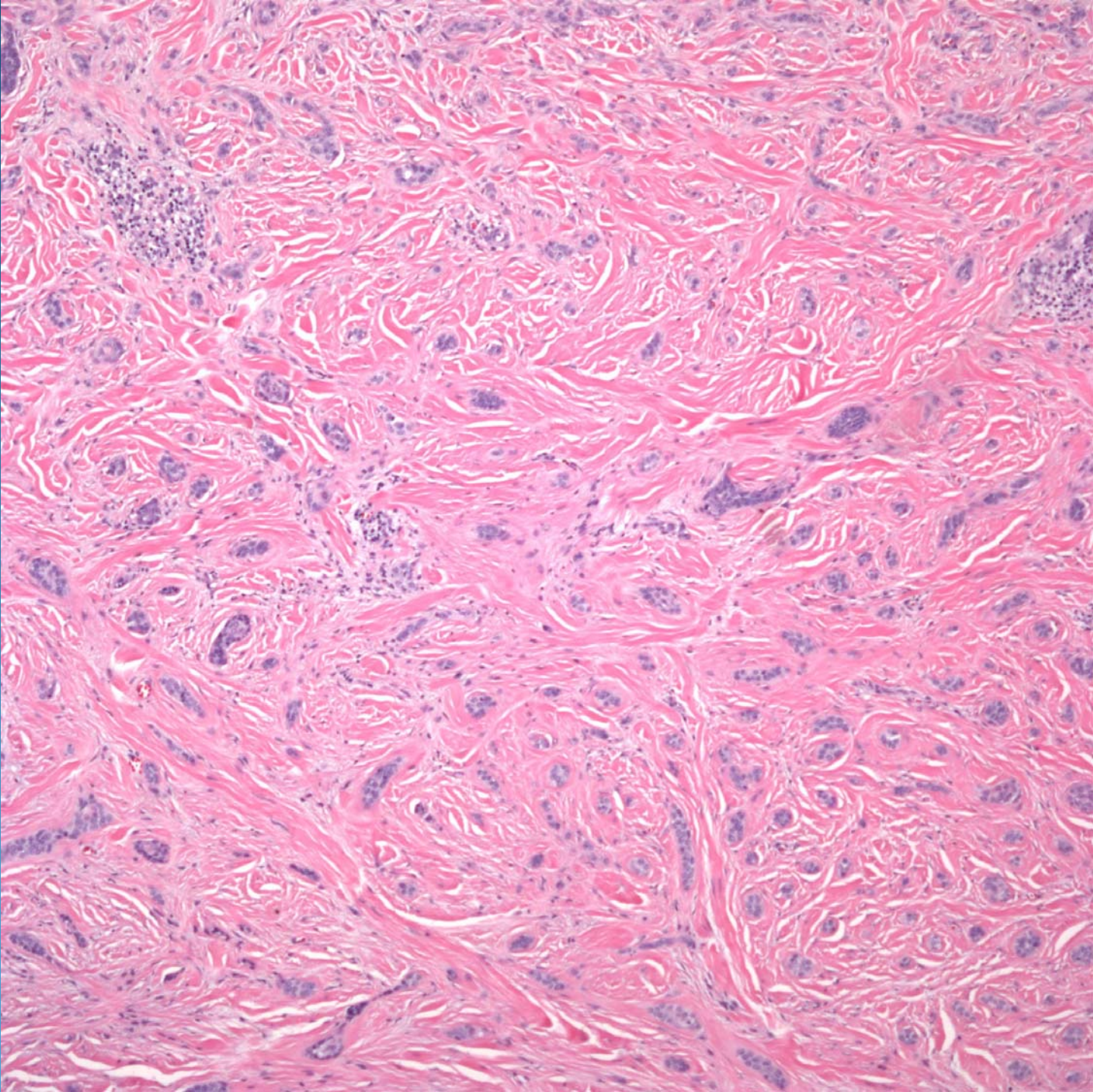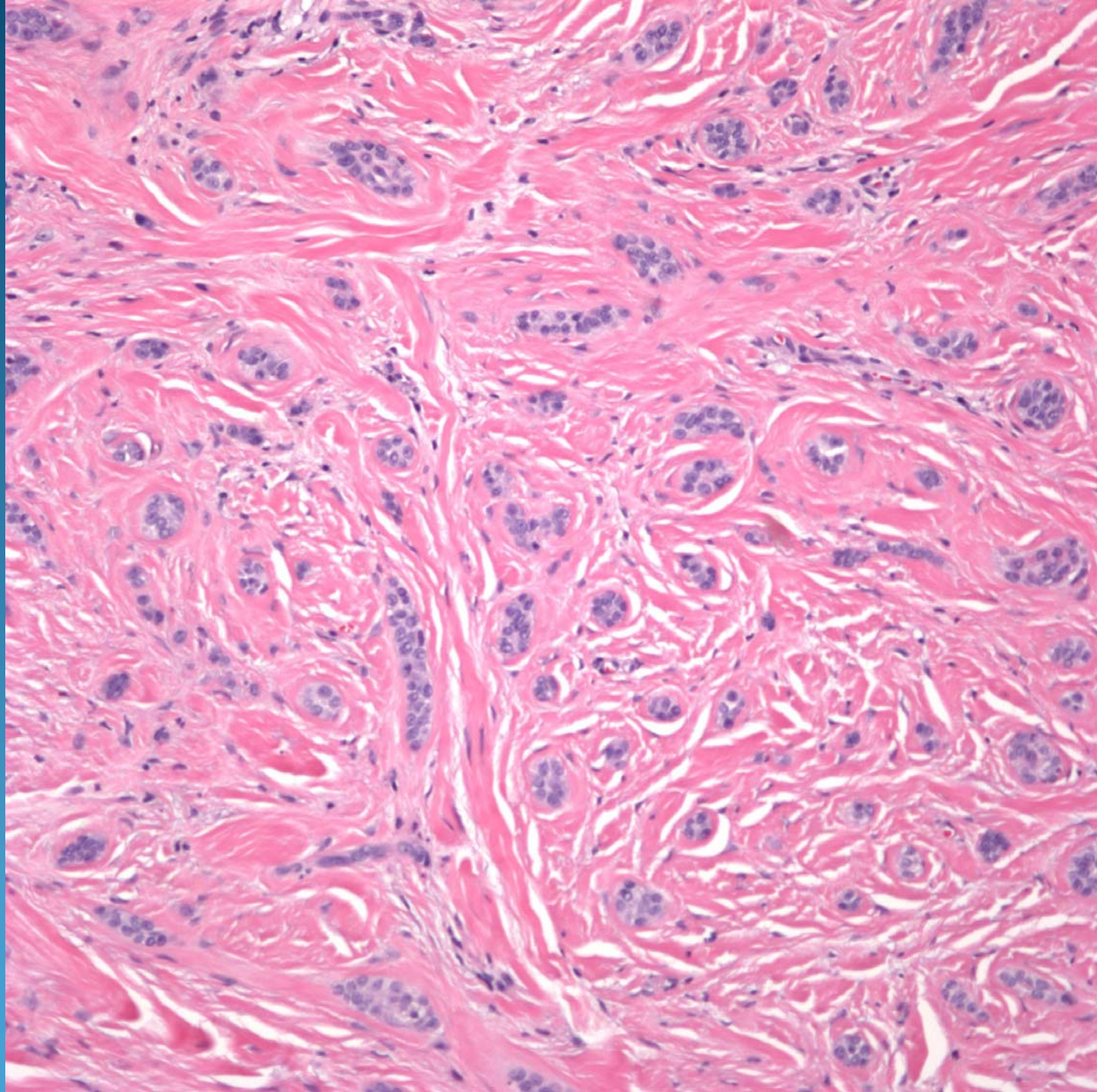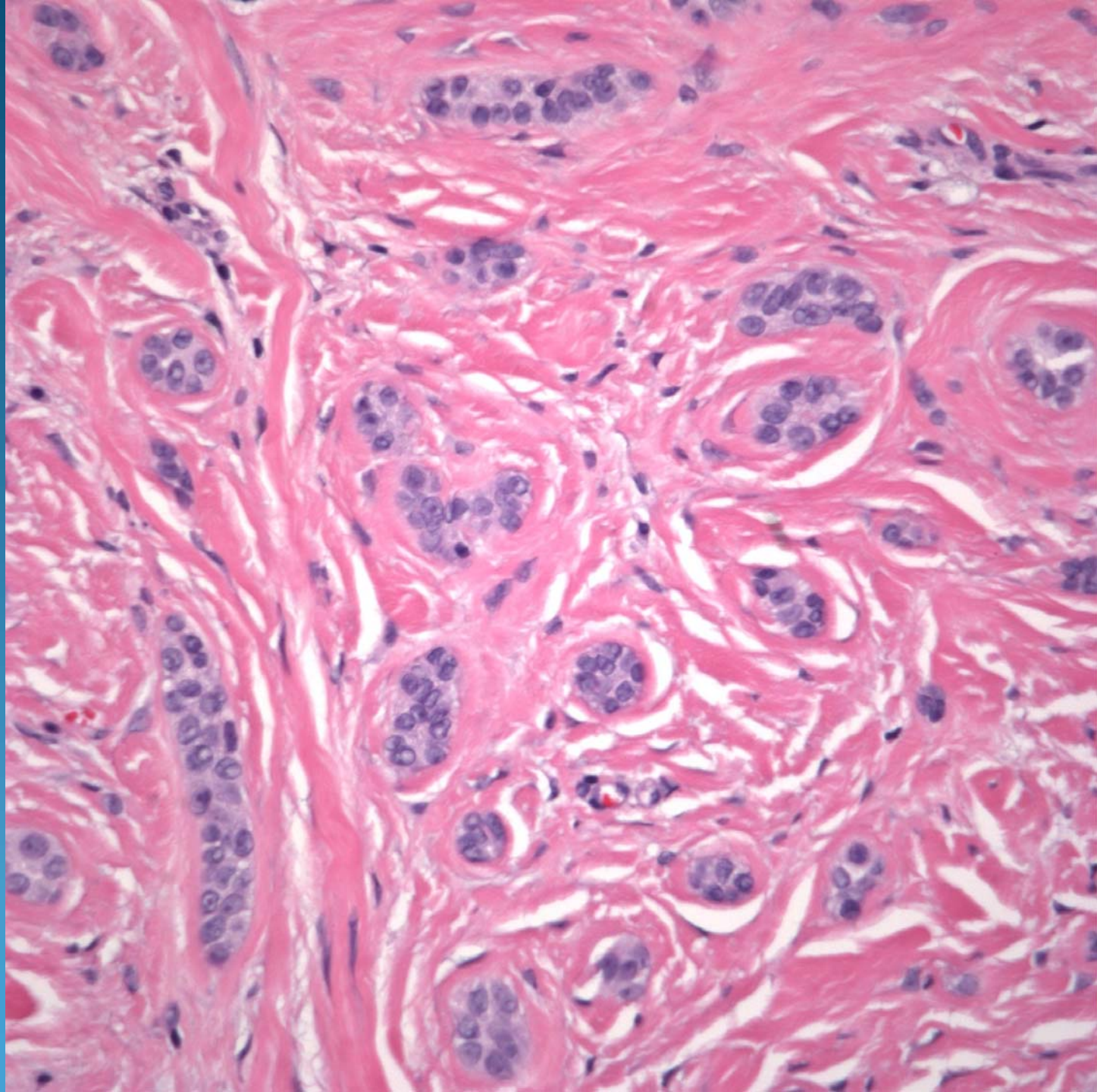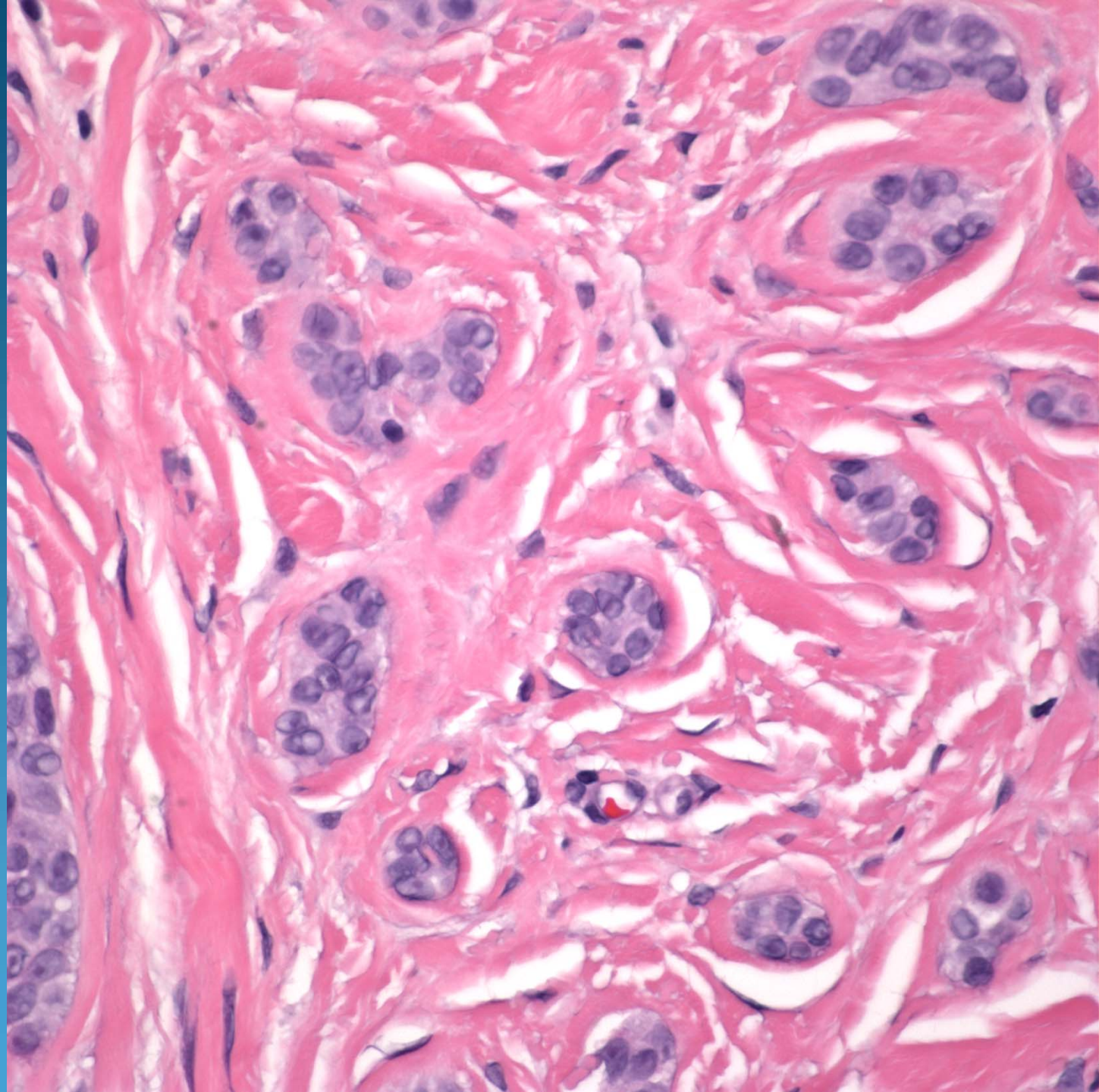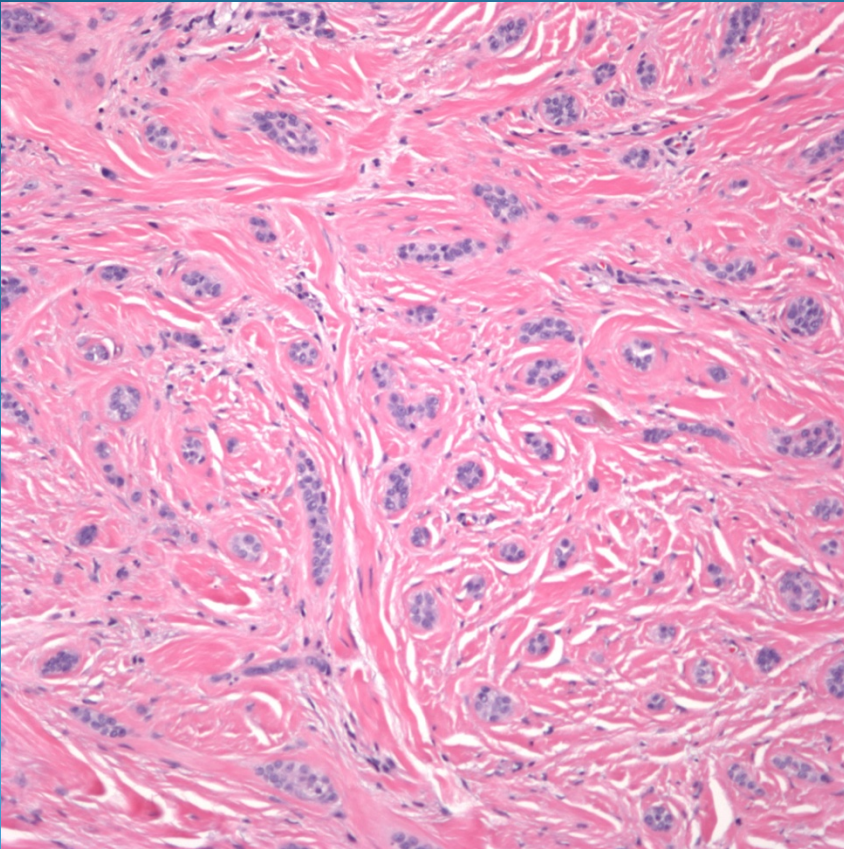


Basal Cell Carcinoma- Morpheaform type

Pearls



- Linear infiltrating strands of cytologically bland epithelial cells
- Generally lacks peripheral palisading and stromal-tumor clefting
- May have desmoplastic stromal host response